



# Brain Aneurysms

## Neurology

Neurocritical care specialists have had a dramatic impact on survival for patients with aneurysmal subarachnoid hemorrhage (SAH). Prospective databases collected in Oxford, England, as well as the Netherlands and Finland, have shown that mortality from SAH over the past 25 years has declined by almost 50%. More remarkably, this has occurred in a setting of stable prevalence of intracranial aneurysms (2-4% of the adult population) and a stable rate of aneurysmal rupture over this same period. What are neurocritical care specialists doing that has resulted in such a dramatic improvement?

Collaboration between neurosurgeons and neurointensivists has been the key to success. Early surgical or endovascular closure of the ruptured aneurysm to prevent rebleeding was the first innovation that was initiated in the late 1980's. Simultaneously, in an aggressive approach to prevent delayed cerebral ischemia (DCI), triple-H therapy was developed (hypertension, hypervolemia, hypoviscosity). Although widely used around the world for decades, triple-H therapy has never been proven in randomized, controlled clinical trials to be effective. Both preoperative and postoperative aggressive control of intracranial hypertension from acute hydrocephalus and brain edema has become standard therapy (external ventricular drainage, hypertonic saline), but more innovative approaches to raised intracranial pressure have been developed (hemicraniectomy, deep sedation with EEG monitoring, therapeutic hypothermia). Scrupulous attention to cardiopulmonary physiology have been essential to maximize brain perfusion and oxygenation. New mechanical ventilation algorithms have been developed to treat neurogenic pulmonary edema, and inotropic stimulation of the heart is used far beyond standard cardiopulmonary management. Our philosophy is to "save the brain" even if it means that we have to strain the heart or the circulatory system. The brain is the only vital organ that cannot be replaced or transplanted, so we use all measures possible to protect it. Successful prevention and treatment of medical complications, including fever, hyperglycemia, hyponatremia, seizures, nosocomial infections, and pulmonary embolism, all contribute to the improved survival of patients with SAH.

Emerging technologies in neurocritical care are helping us to monitor and develop new therapies for delayed cerebral ischemia and brain edema. Intravascular catheters and flow monitors allow us to accurately measure cardiac output and lung water content. Measurement of these parameters allow for physiology-based adjustments of blood pressure, blood volume, cardiac output, intravenous fluids, osmolality, and oxygen administration. Continuous EEG monitoring with computerized algorithms and brain-tissue blood flow and oxygen sensors are used in our standard practice to identify brain ischemia, and brain microdialysis is being developed as an investigational tool to monitor the metabolic products of brain function. Always thinking about recovery, our team has helped to develop a computerized robotic physical therapy system, that results in better functional recovery for our patients than standard physical therapy programs. Our mantra is continuous quality improvement in all aspects of our care and treatment for patients with SAH.

## Neurosurgery

Controversy regarding Open Surgical Clipping versus Endovascular Coiling of Intracranial Aneurysms.

The controversy regarding open surgical clipping versus endovascular coiling of intracranial aneurysms appears to have reached an equipoise. Each aneurysm presents many challenges and treatment is individualized on the basis of multiple factors. Treating physicians consider the tradeoffs between less invasive procedures such as endovascular coiling versus the permanence in securing the aneurysm provided by open craniotomy. The ISAT trial suggests that there is increased morbidity earlier on associated with surgery; however, longer term follow-up demonstrates that there is an increased risk for re-bleeding and recanalization of the aneurysm, requiring repeated procedures with endovascular therapies.

Certain aneurysms present with morphologies that are amenable to either therapy including: characteristics such as having a narrow neck compared to the body of the aneurysm (Figures 1 & 2). However, decisions at large centers such as NewYork-Presbyterian Hospital/Weill Cornell Medical Center, are made on the basis of a multifactorial decision analysis cascade. A patient's clinical picture is evaluated for factors such as the severity of the bleed, the presence of mass effect from a large blood clot, medical comorbidities, the time of presentation after a hemorrhage, and finally the aneurysm's morphology and location within the vasculature.

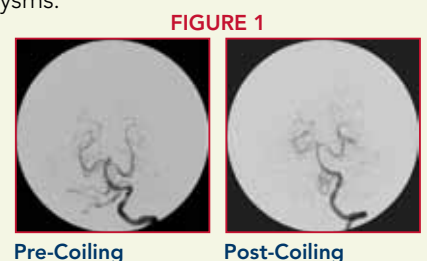
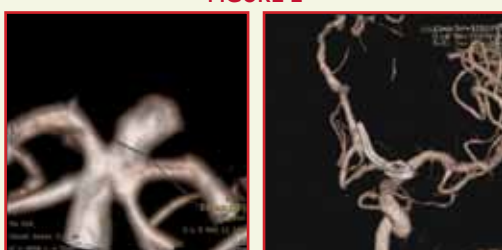

FIGURE 1

Pre-Coiling

Post-Coiling

FIGURE 2




Pre-Clip

Post-Clip

At Weill Cornell Medical Center, a large team of neurosurgeons, interventional radiologists, neurointensivists, and anesthesiologists specializing in the management of cerebrovascular disease, weigh in on the most appropriate therapy for an individual patient.

With this approach, we have found that excellent clinical results can be achieved. For more information, please visit our website at [www.cornellneurosurgery.org](http://www.cornellneurosurgery.org) or call 212-746-4684.



# Weill Cornell Medical College

## Brain and Spine Center

June 2010

### Editorial Board

**Philip E. Stieg, PhD, MD**  
Neurosurgeon-in-Chief  
Department of  
Neurological Surgery



**Matthew E. Fink, MD**  
Neurologist-in-Chief  
Department of Neurology



**Amy Sabek**  
Physician Liaison  
Neuroscience Service Line  
TEL: 212.746.9819  
E: ams2008@nyp.org

**Erina Kim**  
Project Manager  
Neurological Surgery  
E: erk2008@med.cornell.edu

## Upcoming CME Activities and Other Events

### ADVANCED ENDOSCOPIC SKULL BASE AND PITUITARY SURGERY

June 11-12, 2010

This 2-day CME course is a comprehensive overview of the newly emerging field of endoscopic skull base surgery combining didactic sessions with hands-on cadaver dissection.

For more information, please contact Denise Beaulieu at deb2016@med.cornell.edu or visit [www.cornellneurosurgery.org](http://www.cornellneurosurgery.org)

### MONTHLY MULTIPLE SCLEROSIS CME SYMPOSIUM: IS MS A GRAY MATTER DISEASE?

June 16, 2010

6:00pm – 6:45pm – Registration/Reception • 6:45pm – 8:00pm – Lecture

Guest Speaker: Samia Khoury, MD, Professor of Neurology, Harvard Medical School

For more information and to register, visit [www.cornellneurology.org](http://www.cornellneurology.org)

### INDICATIONS AND CONTROVERSIES OF MINIMALLY INVASIVE SPINE SURGERY AND NAVIGATION: *HANDS-ON SYMPOSIUM*

Dec. 2, 2010; 12:00pm – 5:30pm

Dec. 3, 2010; 7:30am – 5:30pm

Dec. 4, 2010; 7:30am – 12:00pm

This symposium will provide a comprehensive overview on new and less invasive techniques with and without stereotactic navigation for the operative treatment of spinal disorders. *CME pending.*

For more information, please contact Jessica Grajales at jeg9059@nyp.org

For these and other active clinical trials, visit our website at <http://www.cornellneurosurgery.org/research/clinical-trials.html>

- MAPS (Matrix and Platinum Science) Trial  
A prospective randomized multi center clinical trial. Patients will be randomized to treatment with bare platinum or bio-polymer coated coils.
- Wide-Neck aneurysms: The Neuroform Stent & the Enterprise Stent System  
Clinical study of devices used under an HDE. These two stents are small metallic mesh tubes designed to keep the coils in the aneurysm sac, in intracranial wide neck aneurysms.
- Comparison of Digital Subtraction angiography vs. MRA for the detection of recurrence of intracranial aneurysms following obliteration with platinum coils.
- ONYX Liquid Embolic System for Aneurysms  
This is a study using an artificial material used to block blood flow into aneurysms. Onyx is indicated for treatment of intracranial, saccular, sidewall aneurysms that present with a wide neck and are not amenable to treat with surgical clipping. This study is under a Humanitarian Use Device.
- COCA: Complete Occlusion of Complex Aneurysms using Pipeline™ embolization device.
- Retrospective Aneurysm Review

## ACTIVE CLINICAL TRIALS:

Weill Cornell Medical College  
Department of Neurosurgery  
525 E. 68th St., Box 99  
New York, NY 10065

NONPROFIT  
ORGANIZATION  
US POSTAGE  
PAID  
NEW YORK NY  
PERMIT # 3036